

Telemedicine in EUROREGION POMERANIA – POMERANIA Network



Norbert Hosten and Przemyslaw Nowacki

- What is TELEMEDICINE?
- Doctors treating patients over a distance with technical support
- An example:
Teleradiology - not enough radiologists - at night the patient in a small hospital is examined by an assistant using x-rays - using the web digital x-ray images are forwarded to a central radiology department - the central department is large to have a radiologist - doctor on site at all times - images are analyzed and reported on - report is forwarded to the hospital where the patient was examined

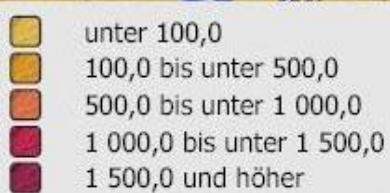
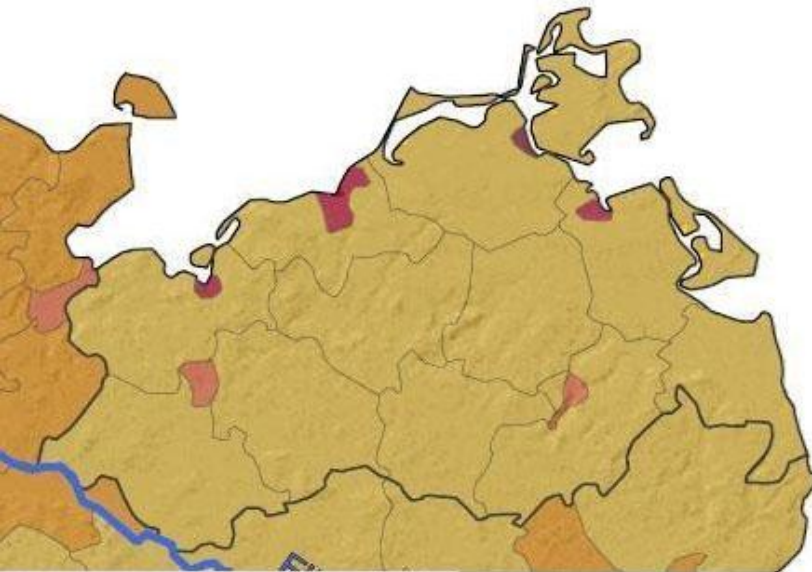
Other tele-scenarios in medicine

- Always: hospital not large enough to support a specialist at all/at all times
 - tele-ophthalmology
 - tele-ear-nose-throat (ENT)
 - tele-pathology
 - sub-specialty
 - tele-tumor-conference
 - tele-conference

Legal framework

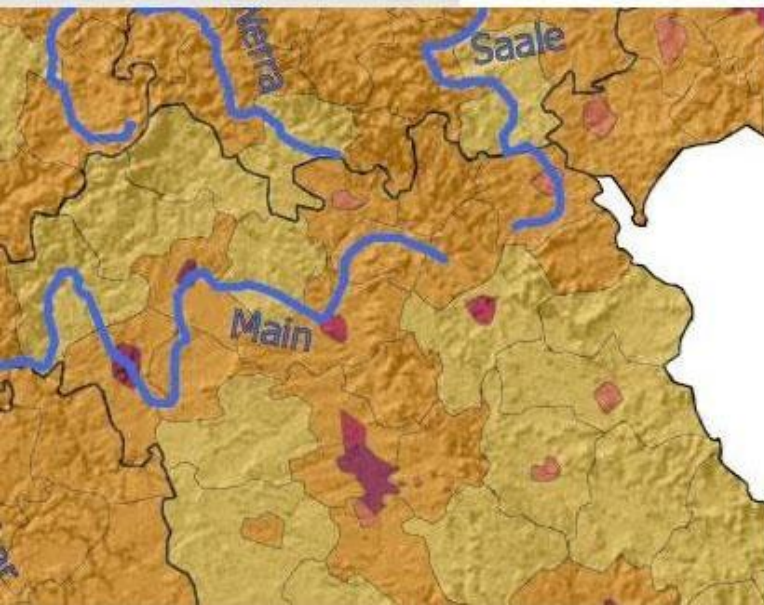
- prohibition of remote treatment (=Fernbehandlungsverbot):
it is illegal for a doctor to treat a patient who is not physically present
- different regulatory framework in many European Countries

Population density Vorpommern



- Vorpommern 74 inhab./km²

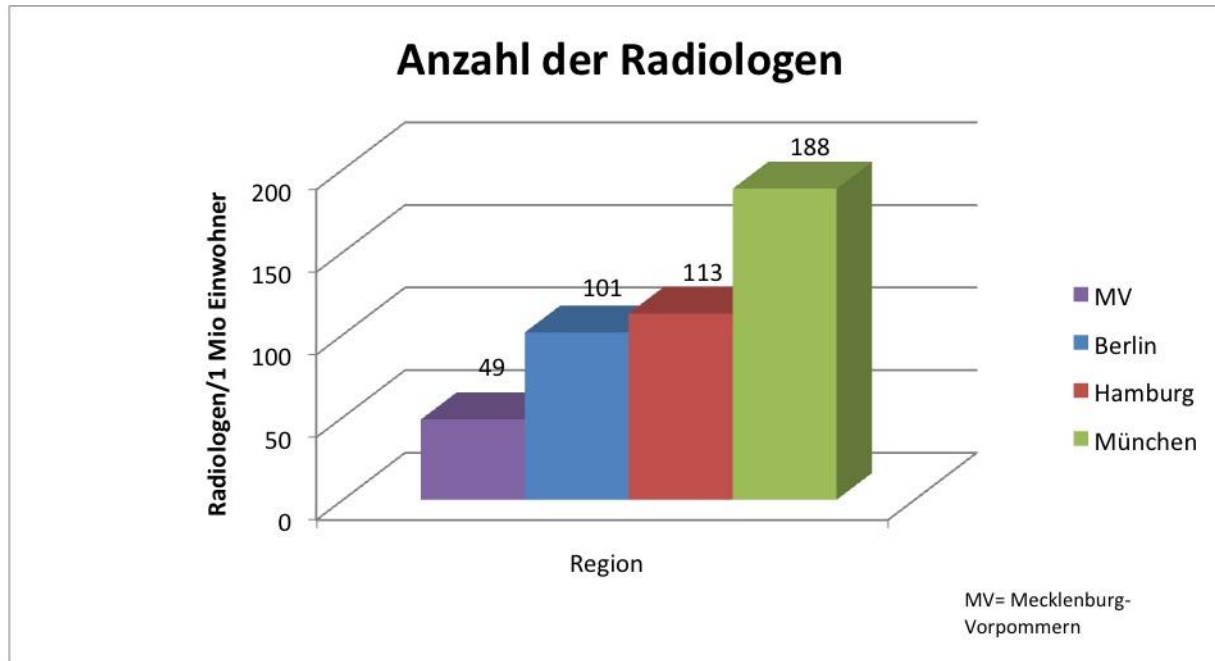
- Greifswald 53.434
- Stralsund 58.288
- Neubrandenburg 67.517



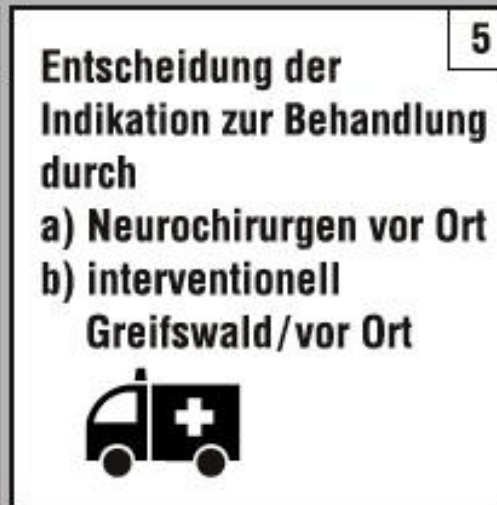
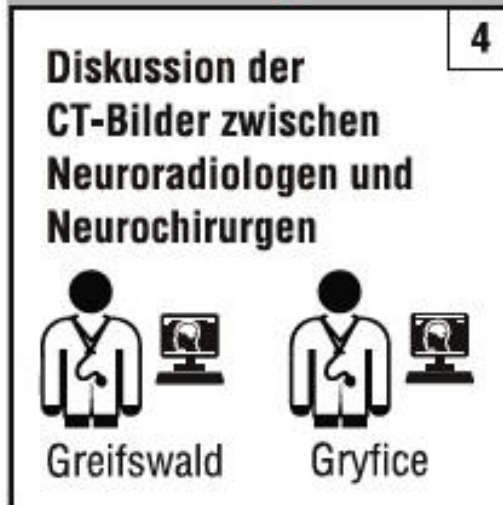
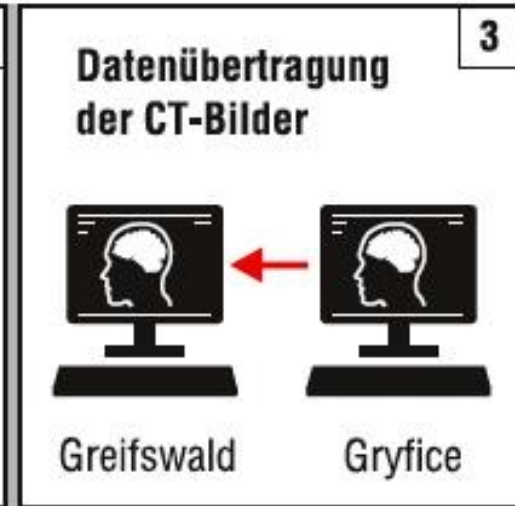
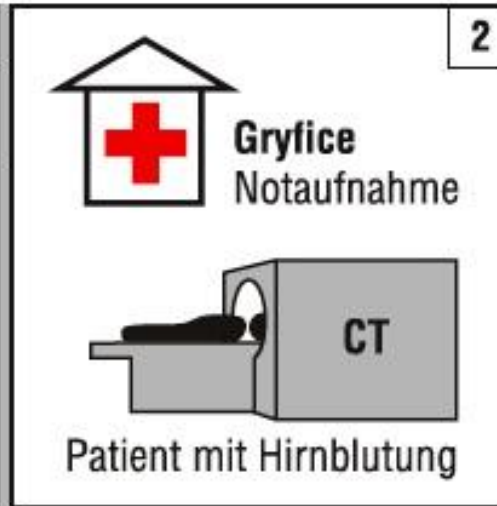
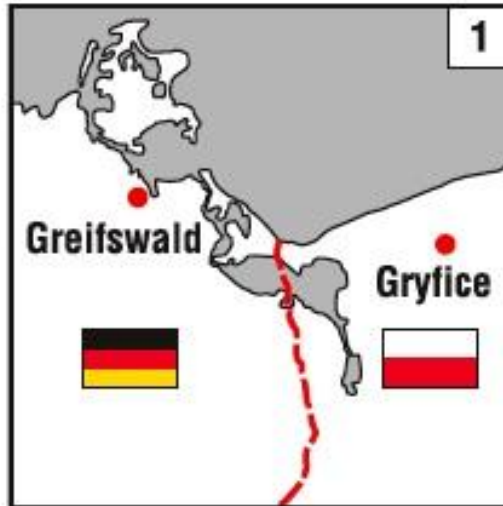- Oberfranken 152 inhab./km²

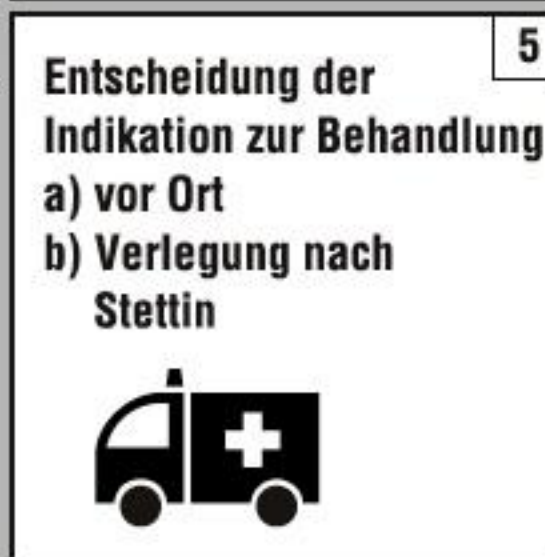
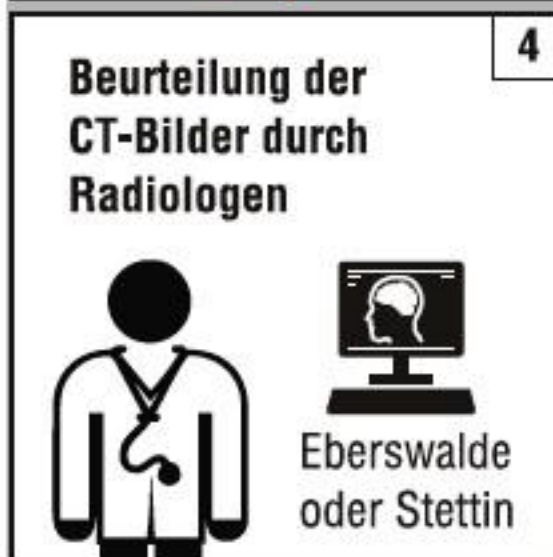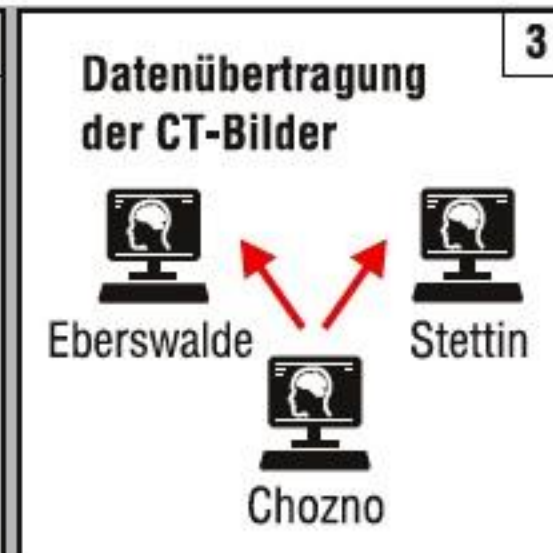
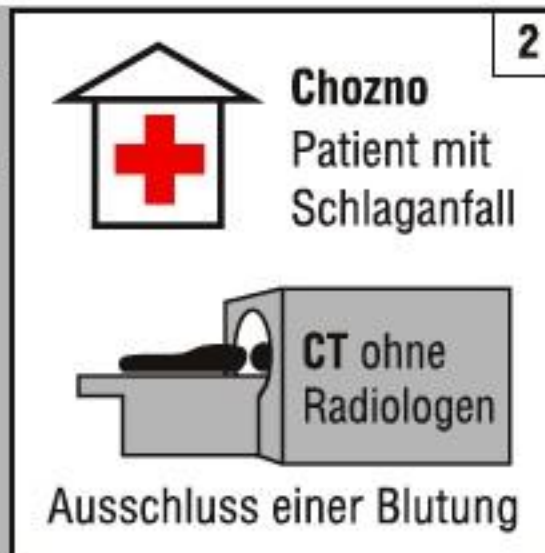
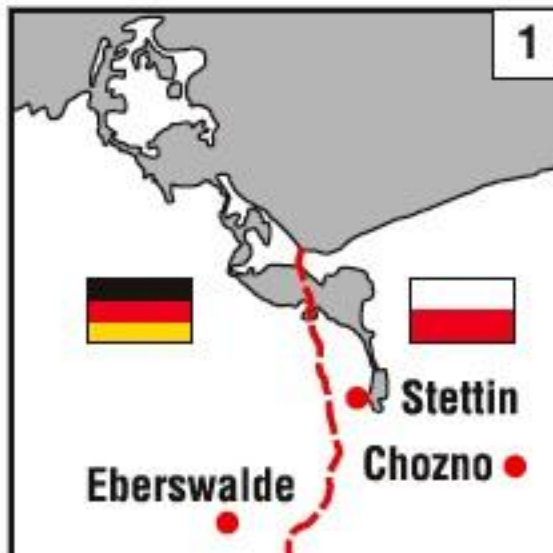- Bamberg 70.063
- Bayreuth 73.202
- Coburg 42.015
- Hof 48.124

Number of Radiologists / 1 mio. inhabitants



- Sweden 120/ 1 mio.
- UK 40/ 1 mio.





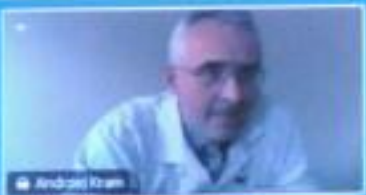
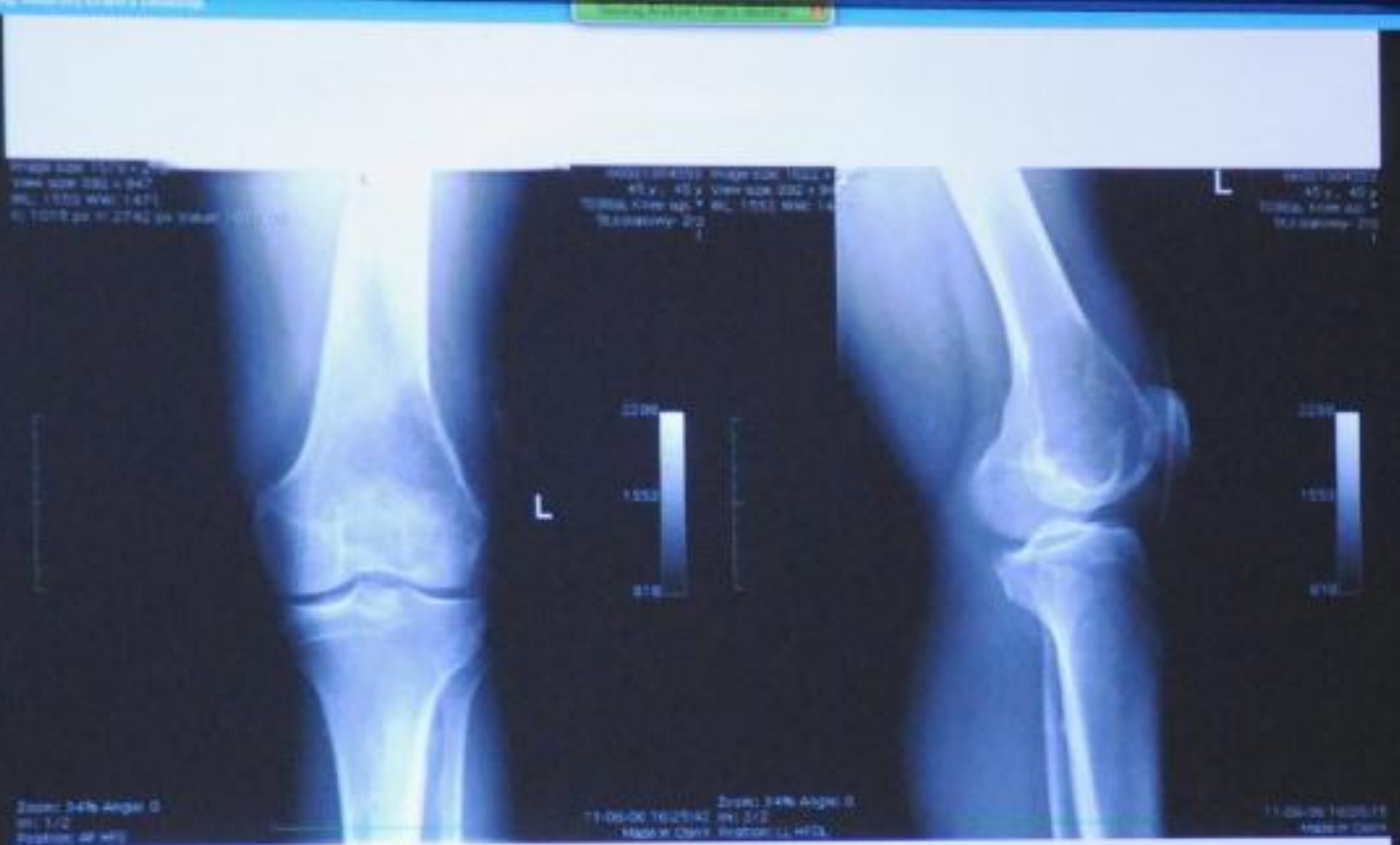Bone cancer

- rare disease
- special expertise in Szczecin
- teaching cross-border for radiology assistants is a technicality





The screenshot displays a telemedicine interface. The main window shows a histological slide of a brain tumor, likely a glioma, characterized by a dense population of cells with hyperchromatic nuclei and a fibrillary background. A large, irregular, pale area is visible, possibly representing necrosis or a cystic component. On the left side, there is a vertical toolbar with four thumbnail images of different histological sections. At the bottom left, a video window shows a man in a white lab coat, identified as 'Andreas Klein'. At the bottom right, there is a 'Recorder' window with a progress bar and a 'Recording' indicator. The Windows taskbar at the bottom shows the 'Start' button and several open applications.





monthly meeting -
Szeczin

German-Polish
working group



grant



monthly meeting -
Neubrandenburg

Verein „Telemedizin Euroregion POMERANIA e.V.“

CEO's

